

## CASE STUDY

# Upper Cervical Chiropractic Care for a Patient with Chronic Migraine Headaches with an Appendix Summarizing an Additional 100 Headache Cases

Erin L. Elster, D.C.

### ABSTRACT

**Objective:** To review the effectiveness of chiropractic care using an upper cervical technique in the case of a 35-year-old female who presented with chronic daily tension and migraine headaches, and to summarize, in an Appendix, the examination findings and results for 100 additional chronic headache cases.

**Clinical Features:** At age 23, the patient, a professional ice skater, sustained a concussion by hitting her head against the ice. Prior to the concussion, no health problems were reported. Following the concussion, tension and migraine headaches ensued. Symptoms persisted over the next twelve years, during which time the patient utilized daily pain medications.

**Intervention:** During the patient's initial chiropractic examination, evidence of a subluxation stemming from the upper cervical spine was found through thermographic and radiographic diagnostics. Chiropractic care using an upper cervical technique was administered to correct and stabilize the patient's upper neck injury. Diagnostics and care were performed in accordance

with the guidelines of the International Upper Cervical Chiropractic Association.

**Outcome:** Evaluation of the patient's condition occurred by doctor's observation, patient's subjective description of symptoms, and thermographic scans. All headaches were absent following three months of care. At the conclusion of her case at one year, all symptoms remained absent.

**Conclusion:** The onset of the symptoms following the patient's fall on her head; the immediate reduction in symptoms correlating with the initiation of care; and the complete absence of all symptoms within three months of care; suggest a link between the patient's concussion, the upper cervical subluxation, and her headaches. Further investigation into upper cervical trauma as a contributing factor to headaches should be pursued.

**Key Indexing Terms:** *upper cervical spine, chiropractic, migraine, cluster, tension, sinus, headache, trauma, thermography*

### INTRODUCTION

The following case report describes a 35-year-old professional ice skater's fall on her head at age 23; the onset of headaches following the blow to the head; the intervention of chiropractic care utilizing an upper cervical technique; and her symptomatic response. An appendix details the examination findings and results utilizing the same upper cervical chiropractic procedure in 100 additional chronic headache cases.

Reports documenting successful treatment of patients with headaches using chiropractic care are limited primarily to Palmer's research conducted seventy years ago (using a similar upper cervical technique), which was never published in a peer-reviewed, indexed fashion.<sup>1-2</sup> Palmer's chiropractic care included paraspinal thermal scanning using a neurocalometer (NCM), a cervical radiographic series to analyze upper cervical misalignment, and a specific upper cervical adjustment performed by hand. Positive results (symptoms were dramatically improved

and/or eliminated) were achieved in approximately 1000 headache cases (from 5000 Palmer Research Clinic cases) whose upper cervical subluxations were corrected.

The rationale for the use of chiropractic care in this case was to correct the patient's upper cervical subluxation that was discovered during her initial evaluation. Patients with other neurological conditions such as Parkinson's disease and Multiple Sclerosis, who presented with similar upper cervical subluxations, also responded favorably to chiropractic intervention.<sup>3-4</sup> It should be noted that, in such cases, patients reported a substantial blow to the head or whiplash injury prior to the onset of symptoms and diagnoses. This case suggests a correlation between a blow to the head, upper cervical subluxation, and neurological disease, and serves to establish a foundation for future research.

Erin L. Elster, D.C., Private Practice, Boulder, CO 80303

## CASE REPORT

This 35-year-old female attended a chiropractic evaluation and recalled her health history following a concussion twelve years prior. Medical records obtained from the patient's neurologist confirmed her history, diagnoses, and treatment.

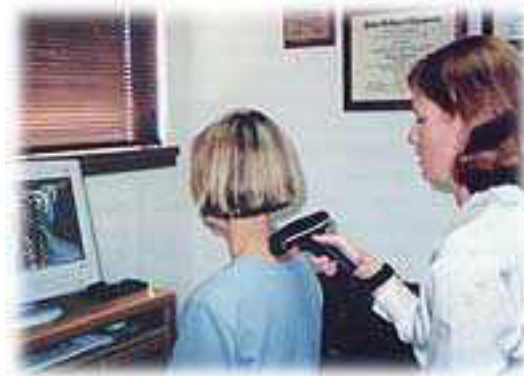At age 23, the patient, a professional ice skater, fell and hit her head against the ice. She was temporarily rendered unconscious and diagnosed with a concussion.

In the ensuing months, she noticed the onset of headaches. The headaches worsened in frequency and severity over time. She thought the heavy headdresses she wore as costumes in ice skating performances aggravated the headaches. She stated that migraine headaches occurred every month during her menstrual period and usually two to three times throughout the other three weeks of a month. Lesser headaches occurred every day in between the migraines. At approximately age 29, she thought the headaches increased in severity and frequency. She reported that she awakened everyday with a headache and rarely went to sleep without one. In describing the headache location, she stated that the pain started in her neck or base of her skull and then spread to her forehead, temple, or side of her head. Although she never experienced aura preceding migraine onset, she often suffered with nausea and vomiting. She reported she took Tylenol with codeine almost every night in order to sleep through the pain, Ibuprofen several times per week, and Maxalt with every migraine. Her physician recommended she incorporate stress reduction, good sleep, hydration, nutrition, exercise, and eliminate "food triggers", but her

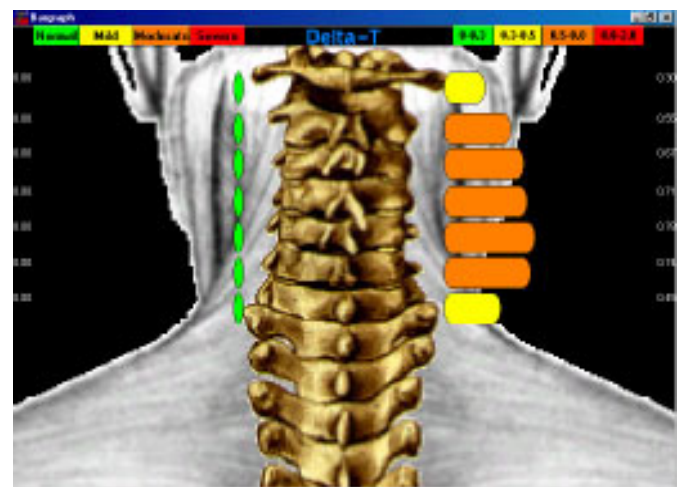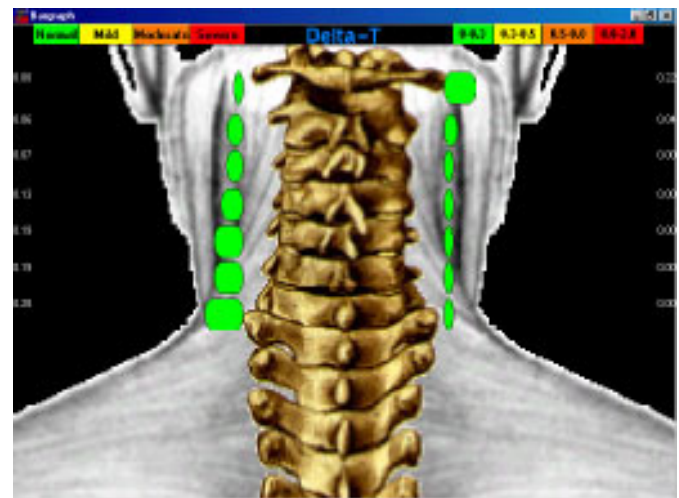headaches continued. Her sister, a massage therapist who frequently massaged the patient, said her right trapezius muscle was chronically hypertonic.

After the patient's medical history was recorded, her evaluation was performed in accordance with the guidelines of the International Upper Cervical Chiropractic Association (IUCCA) through their Applied Upper Cervical Biomechanics (AUCB) program.<sup>5</sup> It should be noted that there are numerous chiropractic techniques that focus upon the upper cervical spine; however, only the technique used in this case will be discussed in this report.

A paraspinal thermal analysis was performed with the Tytron C-3000 (Figure 1- Titronics Research and Development) from the level of C7 to the occiput according to thermographic protocol.<sup>6-8</sup> (Figure 2) Paraspinal digital infrared imaging, which measures cutaneous infrared heat emission, is a form of thermography, a neurophysiological diagnostic imaging pro-



**Figure 1: A patient being scanned with the Tytron C-3000 system**



**Figure 3: Example of cervical side to side thermal comparison. Normal scan (top), Thermal Asymmetries at multiple levels (bottom).**

**Figure 2**

### Tytron C-3000 Thermographic Protocols

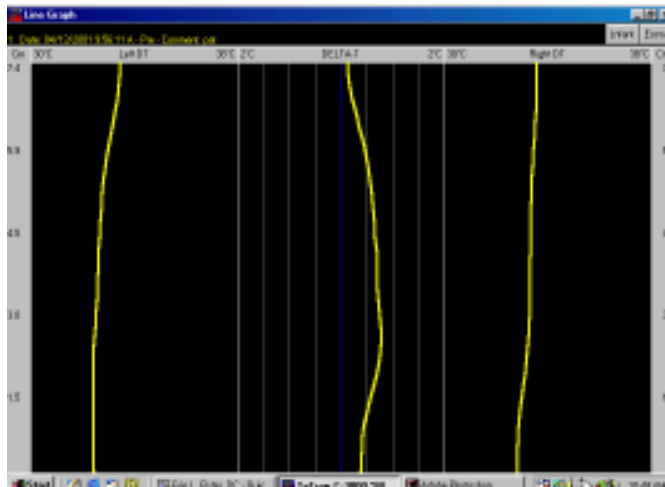
#### Environmental Controls —

- The temperature of your office should be held around 70 degrees Fahrenheit.
- No direct cooling or heating vent drafts should bear on the scanner.
- The scanner should not be placed in direct sunlight.
- Place the scanner holder away from the computer monitor and CPU.

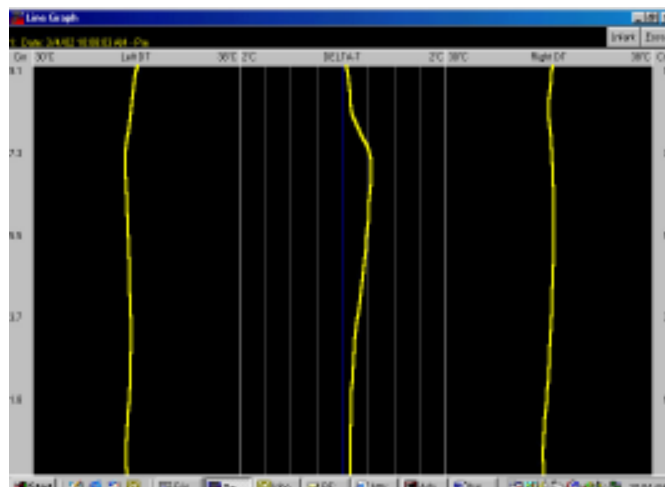
#### Patient Preparation —

- 15 minutes of office acclimation time must occur before scanning the patient.
- The patient's spine must be disrobed or loosely gowned during acclimation.
- The patient must remain free from direct heating or cooling drafts.
- No direct sunlight should bear on the patient while in the office.
- No EMS, TENS, US, hot or cold packs, or acupuncture before scanning.
- The patient must be free from sunburn.

**Figure 4: Establishment of static pattern.**



**Scan 1**



**Scan 2**

cedure. Thermography has been established in chiropractic as a practical and sensitive test for spinal nerve root irritation, articular facet syndromes, peripheral nerve injuries, sympathetic pain syndromes, and the vertebral subluxation complex.<sup>9-11</sup> Since the amount of blood passing through the skin is directly controlled by the sympathetic nervous system (through control of dilation or constriction of blood vessels), the temperature of any one area of the skin reflects the neurological control of that area. Normal or abnormal skin temperature then becomes an indicator of normal or abnormal neurological function. In blind studies comparing thermographic results to that of CAT scan, MRI, EMG, myelography, and surgery, thermography was shown to have a high degree of sensitivity (99.2%), specificity (up to 98%), predictive value, and reliability.<sup>12-14</sup> Thermography has been effective as a diagnostic tool for breast cancer, repetitive strain injuries, headaches, spinal problems, TMJ conditions, pain syndromes, arthritis, and vascular disorders, to name a few.<sup>15-24</sup> A limited number of articles have been published demonstrating the use of paraspinal thermal imaging as an integral part of upper cervical protocol, including reports of patients with Parkinson's disease and Multiple Sclerosis.<sup>3-4</sup>

Compared to established normal values for the cervical spine, the subject's paraspinal scans contained thermal asymmetries of 0.6°C. (Figure 3) According to cervical thermographic guide-

lines, thermal asymmetries of 0.5°C or higher indicate abnormal autonomic regulation or neuropathophysiology.<sup>25-28</sup>

In addition to revealing thermal asymmetries, the subject's scans displayed static thermal differences (Figure 4), thus, a thermal "pattern" was established. "Pattern analysis" of paraspinal temperatures, first developed by Palmer, has received increased attention in chiropractic research.<sup>3-4,29-39</sup>

Because upper cervical misalignments were suspected in this patient, a precision upper cervical radiographic series was performed.<sup>40</sup> The x-ray equipment included a laser-aligned frame (American X-ray Corporation) to eliminate image distortion. To maintain postural integrity, this subject was placed in a positioning chair using head clamps. In addition, the patient was aligned to the central ray using a laser (Titronics Research and Development) mounted on the x-ray tube. The four views (lateral, anterior-posterior, anterior-posterior open mouth, and base posterior) enabled examination of the upper cervical spine in three dimensions: sagittal, coronal, and transverse. Analysis of the four views was directed towards the osseous structures (foramen magnum, occipital condyles, atlas, and axis) that are intimately associated with the neural axis.<sup>40</sup> (Figure 5) Left laterality and left anteriority of atlas was found (Figure 6).

In accordance with AUCB upper cervical protocol, the two criteria used to determine subluxation in this case were thermal asymmetry (measured by paraspinal thermal imaging) and vertebral misalignment (measured by cervical radiographs). Because both criteria (0.6°C thermal asymmetry and left laterality and anteriority of atlas) were met, a care plan was discussed with the patient. In addition, it was recommended that the subject continue her medical treatment and medications unless otherwise advised by her physician.

Following the patient's consent, chiropractic care began with an adjustment to correct the left laterality and anteriority of at-

**Figure 5, Drawing Lines of Mensuration  
(See Figure 6, page 4)**

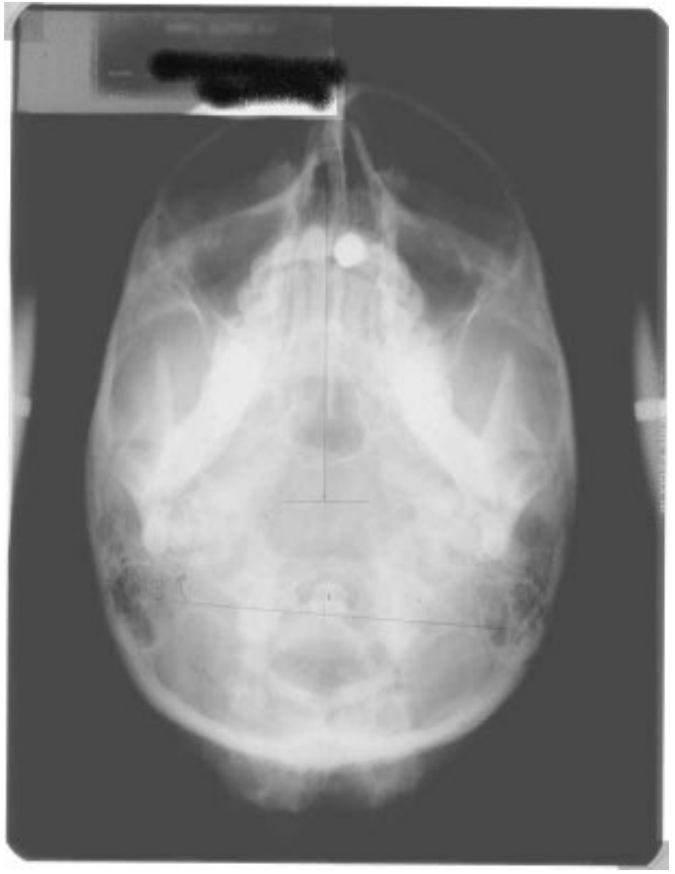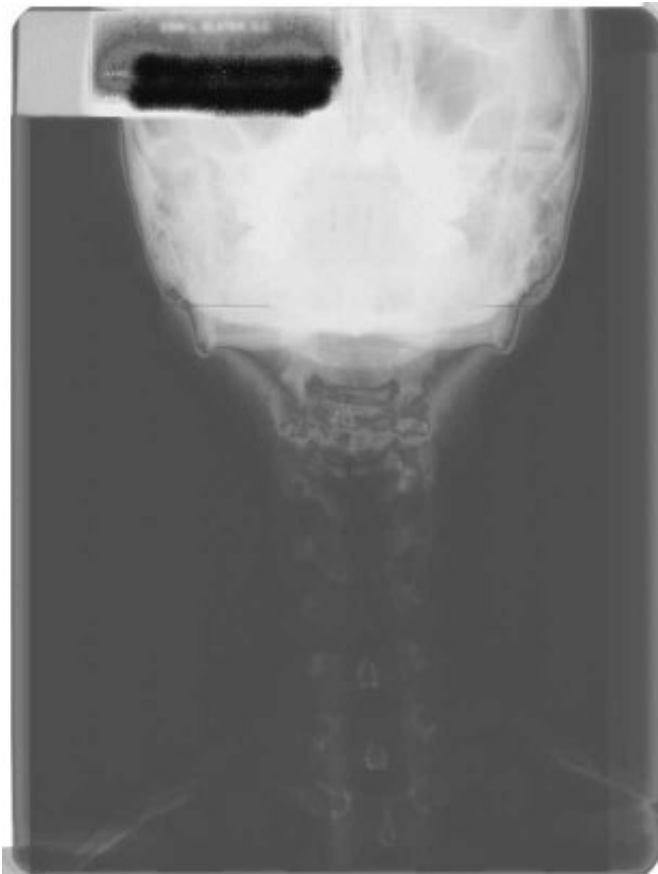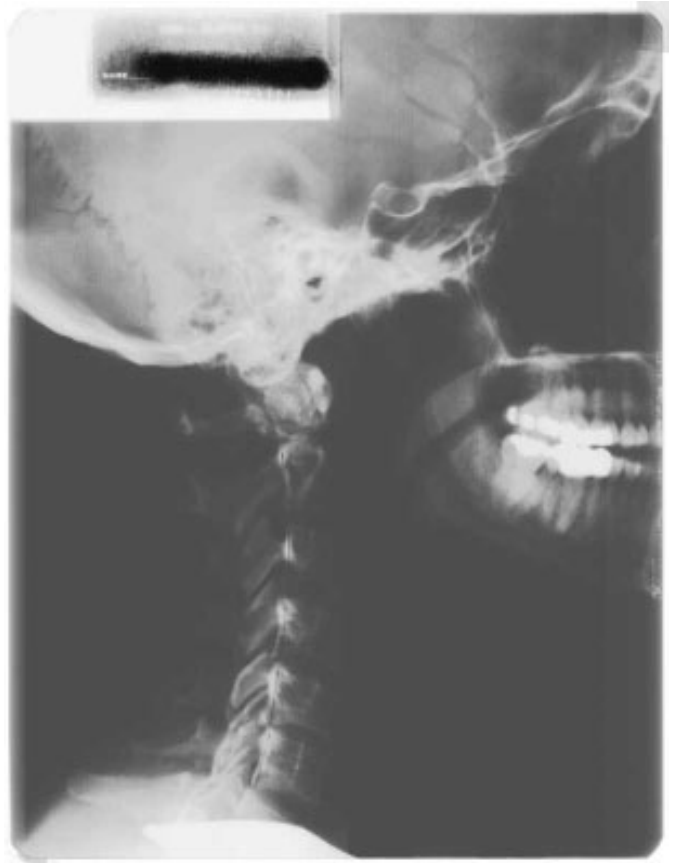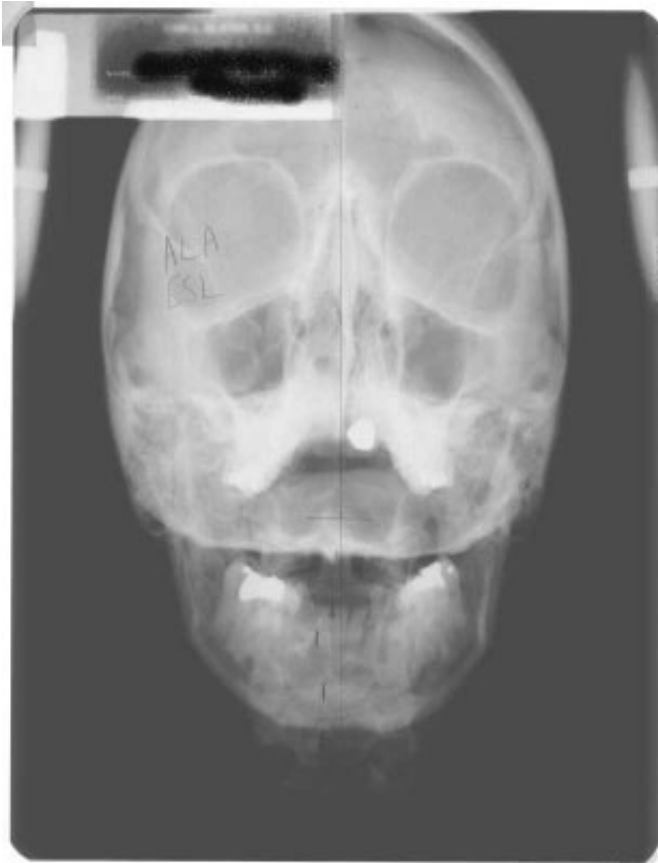To determine laterality from the anterior-posterior open mouth film, a horizontal line was drawn across the upper one-third of the foramen magnum's arch from cortex to cortex. The foramen magnum line was bisected with a vertical median line from the film's top to bottom.

Using a compass's point on the vertical line, arcs were drawn through each lateral mass of atlas. Using the left lateral mass as the constant, if the right lateral mass stayed within the right arc, the atlas was listed as "left". If the right lateral mass extended beyond the right arc, the atlas was listed as "right".

Axis laterality was determined by locating the position of the odontoid and spinous processes according to the vertical median line. To determine atlas rotation from the base-posterior film, an atlas plane line was drawn through the transverse foramen of atlas. The next line was drawn horizontally across the cortical borders of the clivus (ossification center of the skull) from cortex to cortex. This skull line was bisected.

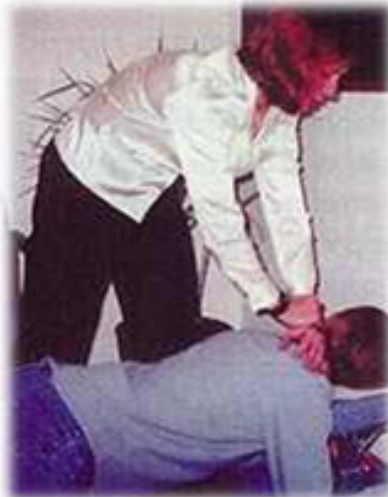Atlas rotation was determined by using a protractor to measure the difference between the bisected skull line and the atlas plane line. An angle less than 90 degrees represented "anteriority". An angle more than 90 degrees represented "posteriority".

**Figure 6: Patient X Rays with Lines of Mensuration**



**See Figure 5, page 3 for explanation of how lines of mensuration were drawn.**

las. To administer the adjustment, the patient was placed on a knee-chest table with her head turned to the left (Figure 7). The knee-chest posture was chosen because of the accessibility of



**Figure 7: Example of patient positioning for knee-chest adjustment.**

the anatomy to be corrected. Using the left posterior arch of atlas as the contact point, an adjusting force was introduced by hand.<sup>41</sup> The adjustment's force (force = mass X acceleration) was generated using body drop (mass) and a toggle thrust (acceleration).

Next, the patient was placed in a post-adjustment recuperation suite for fifteen minutes as per thermographic protocol.<sup>6-8</sup> (Figure 2) After the recuperation period, a post-adjustment thermal scan was performed. The post-adjustment scan revealed a thermal difference of only 0.1 °C, which was considered normal according to established cervical thermographic guidelines (compared to the pre-adjustment differential of 0.6 °C). Therefore, resolution of the patient's presenting thermal asymmetry (elimination of the thermal "pattern") was achieved. (Figures 8 & 9).

All subsequent office visits began with a thermal scan. An adjustment was administered only when the patient's presenting thermal asymmetry ("pattern") returned. If an adjustment was given, a second scan was performed after a fifteen-minute recuperation period to determine whether restoration of normal thermal symmetry had occurred. This subject's office visits occurred two times per week for the first two weeks of care, one time per week for the following four weeks, two times per month for the following month, and one time per month thereafter.

After the first adjustment, during the first two weeks of care, thermal asymmetry was present at two office visits so two adjustments were performed. The patient reported experiencing two severe headaches during the first two weeks of care. She still awakened daily with a headache, but she claimed the pain was milder and that it resolved by the afternoon. She also stated her neck was feeling looser and better and that she required less pain medication.

During weeks three through five, thermal scans were normal so no adjustments were administered. The patient could not recall experiencing any headaches and did not use any pain medication during these three weeks.

Between weeks six and eight, two adjustments were performed and two mild headaches were reported.

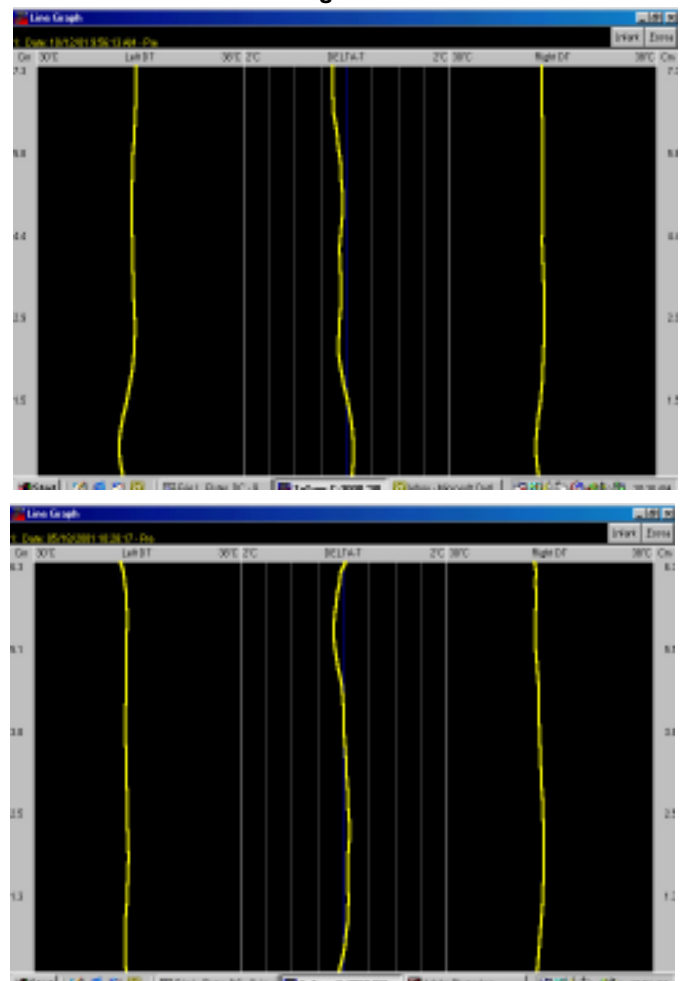
During the third month of care, no adjustments were necessary, no headaches were reported, and no medication was used.

At the end of the third month of care, the subject was involved in an auto accident in which another car unexpectedly turned in front of her. During her office visit the following day, she claimed she was traveling at approximately 30 miles per

hour when she hit the other car. Her symptoms included neck pain and headaches since the accident. She also reported experiencing soreness in her left foot and leg from braking at the time of impact. Her thermal scan indicated a return in thermal asymmetry. Cervical radiographs were retaken to ensure no fractures or dislocations had taken place as well as to determine whether her original x-ray findings had been altered. The films were taken and analyzed as previously illustrated. No change in x-ray listing was found. Accordingly, she was adjusted as previously described. Within a week after this adjustment, all neck soreness and headaches had dissipated and no further adjustments were required.

During the nine months following the accident, the subject was examined once per month. Thermal symmetry was present at each visit, so no adjustments were administered. The patient had not experienced a single headache during that time and had not required any pain medication. During the year of care, no other intervention was reported that could have provided an alternative explanation for the dramatic improvement of the patient's condition.

**Figure 8**



These graphs demonstrate when the patient was not "in pattern" and no adjustment was given on those days.

## DISCUSSION

Consider the case chronology. A healthy, 23-year-old female sustained a concussion by falling on her head. During the subsequent months, tension and migraine headaches ensued. Advice and treatment was sought but the headaches persisted for twelve years. During a chiropractic evaluation utilizing an upper cervical technique, an upper cervical subluxation was found. After the initial adjustment to the patient's upper neck was administered, the patient's symptoms began to subside and continued to improve until absent during the care period.

As the patient was healthy prior to the fall on her head and developed symptoms following the concussion, it follows that the impact had a causal effect on her health problems. Hundreds of medical references substantiate this deduction by naming head and neck trauma as a cause of headaches.<sup>42-62</sup>

Medical references also name the brainstem as a primary site for headache origin.<sup>63-65</sup> According to researchers, migraine headaches have been attributed to malfunctions of the brainstem trigeminal nucleus and brainstem serotonergic pathways that affect nerves and blood vessels in the head. It is thought that abnormal activation of sympathetic nerves triggers vasoconstriction within the brain stem. Consequently, the blood supply to the brain is reduced, causing the dilation of arteries within the brain to meet the brain's oxygen supply. This vasodilation is the source of headache pain.

The relationship between the upper cervical spine and the brainstem is an area requiring further research. Since chiropractic care appeared to stimulate the patient's symptomatic improvements, then it follows that the care may have generated improvement in her brainstem function. The theory discussed below is proposed to explain the relationship between upper cervical subluxation and neurological dysfunction.

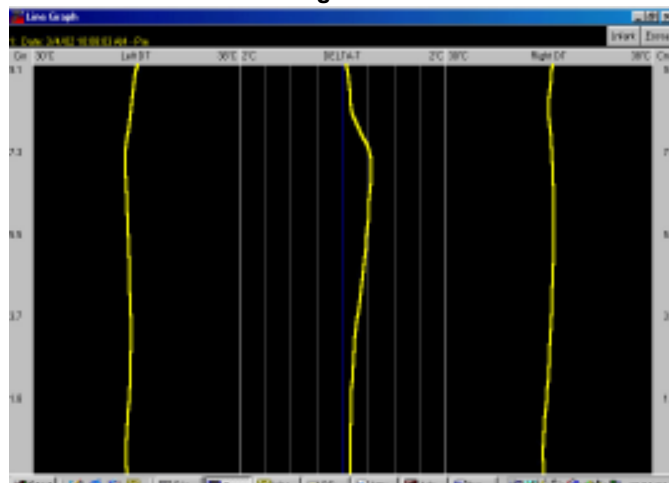
After a spinal trauma, central nervous system facilitation can occur from an increase in afferent signals to the spinal cord and/or brain coming from articular mechanoreceptors.<sup>66-70</sup> The upper cervical spine is uniquely at risk for this problem because it possesses inherently poor biomechanical stability (lacks intervertebral discs and vertical zygapophyseal joints) along with the greatest concentration of spinal mechanoreceptors. Due to central nervous system facilitation from the upper cervical mechanoreceptors, hyperafferent activation of the sympathetic vasomotor center in the brainstem and/or the superior cervical ganglion may occur and may ultimately lead to headaches. Therefore, reversal of the upper cervical injury could alleviate activation of the sympathetic nervous system, thereby eliminating headaches.

In summary, the following hypothesis for the cause and correction of the patient's condition is submitted. The patient's fall on her head caused the spraining of spinal ligaments in her upper neck, allowing for an upper cervical subluxation. Due to the upper cervical subluxation, a variety of complex, detrimental neurological changes developed (probably originating in the brainstem), which ultimately allowed for the manifestation of the patient's headaches. The patient's symptoms remained until the upper cervical subluxation was discovered and reduced. Once the patient's upper cervical alignment was corrected and stabilized, irritation to the central nervous system was eliminated and the patient's normal neurophysiology was restored.

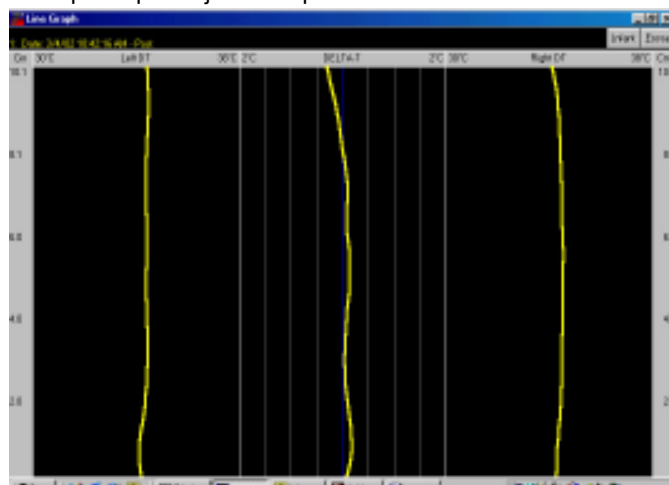## CONCLUSION

This case report details the medical history and symptoms of a 35-year-old female suffering from headaches for twelve years after a fall on her head; the twelve-month intervention of chiropractic care utilizing an upper cervical technique; and the patient's symptomatic response. Evidence of an upper cervical subluxation was found using thermographic and radiographic diagnostics. It was corrected by performing a specific adjust-

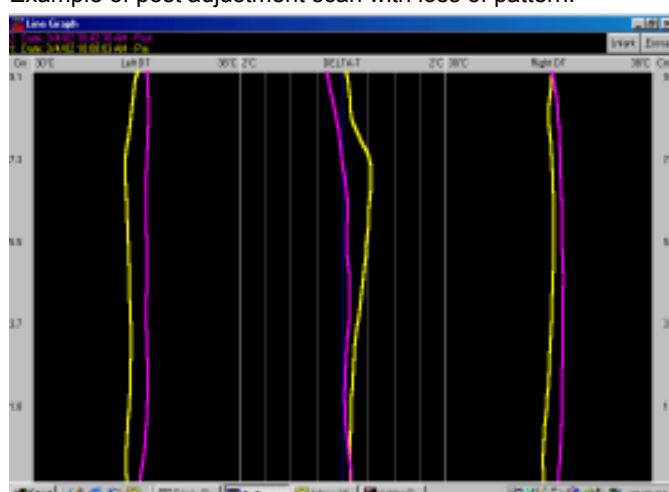
Figure 9



Example of pre-adjustment pattern.



Example of post adjustment scan with loss of pattern.



Example of pre and post scans together.

ment by hand to the first cervical vertebra according to radiographic findings. The upper neck subluxation could have been caused by an ice skating fall in which the patient sustained a concussion. The patient's headaches were absent by the third month of care and remained absent at the conclusion of the patient's case at twelve months.

An additional 100 chronic headache cases, detailed in the Appendix, were examined and cared for using the same upper cervical procedure. Similar favorable results were produced in the majority of patients. To confirm this positive outcome, it is recommended that a more extensive study using control subjects be performed. In addition, further investigation into upper cervical injury and resulting neuropathophysiology as a possible etiology or contributing factor to headaches should be pursued.

#### **APPENDIX: SUMMARY OF 101 CHRONIC HEADACHE CASES**

The appendix summarizes 101 cases (the case study plus 100 additional cases) examined and cared for in the author's private practice over a five-year period in a non-study environment without control subjects and does not purport to be a controlled research study. Rather, this appendix serves to provide a foundation for future research due to the common examination findings in all subjects and the positive results achieved with this upper cervical chiropractic procedure.

All headache patients were examined and cared for with the previously described upper cervical chiropractic procedure, according to the protocol of the International Upper Cervical Chiropractic Association. The four chronic headache categories suffered by the subjects included migraine, cluster, tension, and sinus. From 101 headache patients, 37 migraine cases, 57 tension cases, 1 cluster case, and 6 sinus cases were examined. Patients ranged in age from 5 to 77 years. Frequency of headaches ranged from one headache per month to daily headaches. Patients had experienced headaches between 1 and 57 years. All patients had been diagnosed by their physicians and most had suffered for years in pain and "had tried everything" to find relief including but not limited to pain medications (prescriptions, over the counter, injections, etc.), massage, rolfing, acupuncture, herbs, cervical manipulation, Chinese medicine, bio-feedback, hormone pills, etc.

Statistics of each case (age, gender, headache type, years duration, number of headaches per month before and after care, etc.) are located in Table 1. Upon examination with paraspinal digital infrared imaging, all patients showed static thermal asymmetry of at least .5°C, or thermal "pattern". In addition, all patients' laser-aligned cervical radiographs showed upper cervical deviation from the neural axis. Since all patients showed evidence of upper cervical subluxations upon examination and all patients consented to care, upper cervical care was administered to all 101 patients. Before beginning care, patients were cautioned to continue medical treatments unless otherwise advised by their physicians. It should be noted that twenty additional headache patients were examined and accepted for care during the same time period but chose to discontinue care during the early treatment weeks due to personal, financial, or other

reasons. Therefore, those additional patients' data were omitted from this report.

All 101 cases are found in Table 1. The migraine case discussed in the case report, Case 24, will be used to illustrate the table. Column 2 of the table lists the patient's headache diagnosis: migraine (M), tension (T), cluster (C), or sinus (S). Since Case 24 suffered both daily tension and migraine headaches, "T & M" is noted. Columns 3 and 4 list the patient's age (35) and gender (F). Column 5 lists the number of years headaches were present before the patient sought help from upper cervical care (12 years for Case 24). Column 6 lists the number of months of care required to achieve the substantial reduction or elimination of headaches. Since Case 24 was headache-free by the third month of care, "3" is listed. Column 7 lists the degree of thermal deviation in each patient's paraspinal thermal scan (.6°C for Case 24). Column 8 lists each patient's upper cervical x-ray listing (ALA for Case 24). Atlas listings are depicted with laterality of left (L) or right (R) and rotation of anterior (A) or posterior (P). The lateral movement of axis is listed to the left (ESL) or right (ESR). Finally, Column 9 lists whether a patient recalled a trauma to his/her head and/or neck that could have caused the upper cervical subluxation found during examination. Since Case 24 recalled multiple falls on the ice as a professional ice skater including one concussion, "yes" was noted. Columns 10 and 11 list the number of headaches suffered per month prior to and subsequent to upper cervical care. Since Case 24 suffered daily headaches prior to upper cervical care and no headaches after care, "30" and "0" are listed.

From a total of 101 cases, 85 patients' headaches were completely resolved within 1 to 8 months of upper cervical care. Twelve of the remaining cases were improved in that their headaches were greatly reduced but some residual headaches occurred. All patients under the age of 18 had their headaches resolved within two months of care. Most adult cases were resolved within four months. Some subjects required six months or more to achieve maximum benefit, but these were patients who had suffered with headaches for many decades. Four cases showed little to no improvement.

When questioned, 87 of 101 patients recalled at least one specific traumatic event (fall, accident, whiplash, concussion) that preceded their headache onset and could have caused their upper cervical subluxation. The most common traumas included whiplash and/or concussion as a result of auto accidents and traumas during sports including skiing, cycling, horse back riding, ice skating, football, gymnastics, snow boarding, skate boarding, etc. Frequently, parents of children with headaches reported that their child had a difficult birth requiring forceps or suction and concluded that perhaps birth trauma had been the source of their child's upper cervical injury.

#### **ACKNOWLEDGMENTS**

The author gratefully acknowledges Drs. William Amalu and Louis Tiscareno of the International Upper Cervical Chiropractic Association (IUCCA) for their Applied Upper Cervical Biomechanics Course and the Titronics Corporation for the Tytron C-3000 Paraspinal Digital Thermal scanner.

Table 1. Data For 101 Chronic Headache Cases

Case No.	HA Type	Age	Gender	Years of HA	# Months of Care	Thermal Deviation	X-Ray Listing	History of Trauma	# HA per Month Before Care	# HA per Month After Care
1	C	44	M	20	2	0.7	ARP	YES	30	0
2	M	44	F	10	5	0.7	ESL	YES	10	3
3	M	48	M	4	1	0.5	ARA	YES	1	0
4	M	52	F	13	8	1.0	AL	YES	4	0
5	M	40	F	10	1	0.7	ALA	NO	2	0
6	M	49	F	4	5	0.5	AL	YES	10	2
7	M	23	F	14	1	1.6	AL	YES	1	0
8	M	25	F	18	3	0.5	ESL	YES	4	0
9	M	47	F	10	1	0.5	ALA	YES	4	0
10	M	47	F	26	2	0.5	ALP	YES	1	0
11	M	28	F	18	6	0.5	ESR	NO	20	4
12	M	59	M	30	2	0.7	ALP	YES	2	0
13	M	23	M	6	6	0.5	ESR	YES	30	0
14	M	53	F	30	3	0.6	ARP	YES	4	0
15	M	48	F	28	6	0.7	ESL	NO	21	2
16	M	46	F	6	2	0.5	ESR	YES	4	0
17	M	46	F	35	8	0.5	AR	NO	16	4
18	M	48	F	35	6	0.5	AL	YES	2	0
19	M	53	F	40	10	0.5	AR	NO	30	25
20	M	24	F	5	1	0.5	ALP	YES	2	0
21	M	25	F	20	3	0.5	ARA	YES	30	0
22	M	27	F	2	3	0.6	ESL	YES	2	0
23	M	42	F	25	2	0.5	ARA	YES	1	0
24	M & T	35	F	12	3	0.6	ALA	YES	30	0
25	M & T	19	F	2	1	1.0	ALA	YES	5	0
26	M & T	49	F	40	2	0.5	ESR	NO	30	0
27	M & T	48	F	35	1	0.7	ARA	YES	5	0
28	M & T	28	F	4	2	1.0	ESL	YES	20	0
29	M & T	67	F	57	6	0.5	AR	YES	4	1
30	M & T	12	F	1	3	0.5	AR	NO	12	0
31	M & T	44	F	36	4	1.0	ALA	YES	30	2
32	M & T	15	F	2	3	1.1	ESL	YES	30	2
33	M & T	9	M	3	1	0.5	AL	YES	10	0
34	M & T	34	F	22	6	0.5	ESL	NO	30	1
35	M & T	43	F	30	4	0.6	AR	YES	10	0
36	M & T	45	F	3	6	0.5	ARP	YES	8	0
37	M & T	45	F	25	7	0.6	AL	YES	30	15
38	M & T	41	F	6	3	0.5	ESL	YES	8	0
39	S	47	M	20	1	0.5	ALP	YES	8	0
40	S	43	F	20	2	0.6	ALA	YES	2	0
41	S	52	F	8	2	0.5	AR	YES	4	0
42	S	16	F	3	2	0.7	ARP	NO	1	0
43	S	36	F	12	6	0.5	AR	YES	30	20
44	S	16	F	9	2	0.5	AR	YES	4	0
45	T	48	F	20	3	0.5	ESR	NO	4	0
46	T	17	F	7	2	0.5	ALA	YES	8	0
47	T	56	F	14	1	0.8	ARP	YES	8	0
48	T	30	M	4	2	0.5	ESL	YES	30	0
49	T	50	F	5	3	0.5	ESL	YES	30	0
50	T	61	F	2	1	0.5	AR	YES	4	0
51	T	26	F	6	3	0.5	ESL	YES	8	0
52	T	46	F	23	3	0.6	ARA	YES	8	0
53	T	36	F	6	1	0.5	ALA	YES	30	0
54	T	11	M	5	1	0.5	ESL	YES	8	0
55	T	62	F	2	5	0.6	ESL	YES	5	0
56	T	41	M	1	3	0.9	AR	YES	10	0
57	T	52	F	2	1	0.9	AR	YES	30	0
58	T	37	F	15	4	0.5	ARA	YES	30	0
59	T	41	F	10	4	1.0	ESR	YES	30	0



Table 1. Data For 101 Chronic Headache Cases (Cont.)

Case No.	HA Type	Age	Gender	Years of HA	# Months of Care	Thermal Deviation	X-Ray Listing	History of Trauma	# HA per Month Before Care	# HA per Month After Care
60	T	60	F	50	6	0.5	ESR	YES	10	2
61	T	28	F	11	2	1.2	ESR	YES	2	0
62	T	28	F	2	4	0.5	AR	YES	30	0
63	T	48	F	40	4	0.5	ESL	YES	30	0
64	T	17	M	10	2	0.5	ARP	YES	5	0
65	T	50	F	1	1	1.5	ARA	YES	5	0
66	T	36	F	17	1	0.6	ALA	YES	5	0
67	T	55	F	2	1	0.5	ESR	YES	5	0
68	T	40	F	20	6	0.5	AL	YES	5	1
69	T	54	F	20	6	0.6	ESR	YES	30	2
70	T	54	M	15	1	0.5	AR	YES	2	0
71	T	48	F	3	4	0.5	ESL	YES	20	0
72	T	52	M	5	2	0.5	AL	YES	5	0
73	T	26	F	1	1	0.5	ARP	YES	8	0
74	T	33	F	10	2	1.0	ARA	NO	4	0
75	T	40	F	7	3	0.5	ESR	YES	30	0
76	T	58	F	1	1	0.7	ARP	YES	2	0
77	T	52	F	2	3	0.9	ESL	YES	30	0
78	T	43	F	12	2	0.5	ARA	YES	4	0
79	T	39	F	1	1	0.6	ALP	NO	30	0
80	T	48	F	1	2	0.5	ESL	YES	2	0
81	T	77	F	2	1	0.5	AL	NO	30	0
82	T	8	F	1	1	0.5	ARA	YES	4	0
83	T	61	F	30	6	0.5	AR	YES	30	0
84	T	25	F	1	2	0.5	ALA	NO	20	0
85	T	21	F	10	1	0.5	ARP	YES	4	0
86	T	35	F	1	1	0.5	ALA	YES	30	0
87	T	50	M	13	5	0.7	AL	YES	30	0
88	T	25	M	1	1	1.3	AR	YES	2	0
89	T	9	M	5	1	0.6	ARA	YES	30	0
90	T	22	M	4	1	0.5	AR	YES	1	0
91	T	40	F	1	1	0.6	AL	YES	4	0
92	T	50	M	1	2	0.5	ARP	NO	12	0
93	T	36	M	29	2	0.6	ALA	YES	15	0
94	T	8	F	2	2	0.8	ARP	YES	30	0
95	T	5	F	1	1	0.7	AL	YES	5	0
96	T	64	F	40	1	0.6	AL	YES	30	0
97	T	15	F	1	2	1.2	ALP	YES	30	0
98	T	44	F	5	6	0.5	ESR	YES	30	15
99	T	32	F	2	4	0.6	ALP	YES	20	0
100	T	40	F	1	1	0.5	ALA	YES	2	0
101	T	16	F	1	2	0.5	ALP	YES	2	0

REFERENCES

- Palmer BJ. The Subluxation Specific The Adjustment Specific. Davenport, Iowa: Palmer School of Chiropractic, 1934: 862-70.
- Palmer, BJ. Chiropractic Clinical Controlled Research. Davenport, Iowa: Palmer School of Chiropractic, 1951.
- Elster E. Upper cervical chiropractic management of a patient with Parkinson's disease: a case report. *J Manipulative Physiol Ther* 2000 Oct; 23(8) 573-7.
- Elster E. Upper cervical chiropractic management of a patient with Multiple Sclerosis: a case report. *Journal of Vertebral Subluxation Research* 2001 May; 4(2).
- Applied Upper Cervical Biomechanics program. www.pacificchiro.com. Redwood City, California: International Upper Cervical Chiropractic Association, 1993.
- International Thermographic Society. Thermography protocols. In: Amalu W, Tiscareno L. Clinical neurophysiology and paraspinal thermography: module 2—applied upper cervical biomechanics course. Redwood City, Calif: International Upper Cervical Chiropractic Association; 1993. p.67-70.
- American Academy of Thermology. Thermography Protocols. In: Amalu W, Tiscareno L. Clinical neurophysiology and paraspinal thermography: module 2—applied upper cervical biomechanics course. Redwood City, Calif: International Upper Cervical Chiropractic Association; 1993. p.67-70.
- American Academy of Medical Infrared Imaging. Thermography Protocols. In: Amalu W, Tiscareno L. Clinical neurophysiology and paraspinal thermography: module 2—applied upper cervical biomechanics course. Redwood City, Calif: International Upper Cervical Chiropractic Association; 1993. p.67-70.
- Amalu W, Tiscareno L, et al. Clinical neurophysiology and paraspinal thermography: module 2- Applied Upper Cervical Biomechanics Course. Redwood City, Calif: International Upper Cervical Chiropractic Association, 1993. p.62-70.
- Amalu W, Tiscareno L. Objective analysis of neuropathophysiology, Part 1. *Today's Chiropractic* 1996 May; 25(3): 90-6.
- Amalu W, Tiscareno L. Objective analysis of neuropathophysiology, Part 2. *Today's Chiropractic* 1996 July; 25(4): 62-66.
- Goldberg G. Thermography and magnetic resonance imaging correlated in 35 cases. *Thermology* 1986; 1: 207-11.

13. Thomas D, Cullum D, Siahamis G. Infrared thermographic imaging, magnetic resonance imaging, CT scan and myelography in low back pain. *Br J Rheumatol* 1990; 29: 268-73.
14. Weinstein SA, Weinstein G. A clinical comparison of cervical thermography with EMG, CT scanning, myelography and surgical procedures in 500 patients. Proceedings of the 1st annual meeting of the Academy of Neuromuscular Thermography; 1985 May. *Postgrad Med* 1986; Special ed: 44-6.
15. Gros C, Gautherie M. Breast thermography and cancer risk prediction. *Cancer* 1980; 45(1): 51-56.
16. Diakow P. Thermographic imaging of myofascial trigger points. *JMPT* 1988; 11(2): 114-17.
17. Drummond PD, Lance JW. Thermographic changes in cluster headaches. *Neurology* 1984; 34:1292-98.
18. Hendler N, Uematsu S. Thermographic validation of physical complaints in psychogenic pain patients. *Psychosomatics* 1982;23.
19. Zellner J, Bandler H. Thermographic assessment of carpal tunnel syndrome. *J Bone Joint Surg* 1986; 10: 558.
20. Weinstein SA, Weinstein G. A protocol for the identification of temporomandibular joint disorder by standardized computerized electronic thermography. *Clin J Pain* 1987; 3: 107-12.
21. Sionni, IH. Thermography in suspected deep venous thrombosis of lower leg. *Europ J Radiol* May 1985; 281-84.
22. Ecker A. Reflex sympathetic dystrophy thermography in diagnosis. *Psychiatric Annals* 1984; 14(11): 787-93.
23. Swerdlow B, Dieter JN. The persistent migraine cold patch and the fixed facial thermogram. *Thermology* 1986; 2:1620.
24. Wood EH. Thermography in the diagnosis of cerebrovascular disease. *Radiology* 1965; 85: 270-83.
25. Uematsu, E, et al. Quantification of thermal asymmetry, part 1: normal values and reproducibility. *J Neurosurg* 1988; 69: 552-555.
26. Feldman F, Nicoloff E. Normal thermographic standards in the cervical spine and upper extremities. *Skeletal Radiol* 1984; 12: 235-249.
27. Clark RP. Human skin temperatures and its relevance in physiology and clinical assessment. In: Francis E, Ring J, Phillips B, et al. *Recent advances in medical thermology*. New York: Plenum Press, 1984, 5-15.
28. Uematsu S. Symmetry of skin temperature comparing one side of the body to the other. *Thermology* 1985; 1:4-7.
29. Hart, J.F., Boone, W.R. Pattern Analysis of Paraspinal Temperatures: A Descriptive Report. *Journal of Vertebral Subluxation Research* 2000; 3(4).
30. Kent C. Paraspinal skin temperature differentials and vertebral subluxation. *The Chiropractic Journal*. September 1997.
31. Schram SB, Hosek RS, Owens ES. Computerized paraspinal skin surface temperature scanning: A technical report. *J Manip Physiol Ther* 1982; 5(3): 117-122.
32. Ebrall PS, Iggo A, Hobson P, Farrant G. Preliminary report: The thermal characteristics of spinal levels identified as having differential temperature by contact thermocouple measurement (Nervo Scope). *Chiropr J of Australia* 1994; 24(4):139-143.
33. Stewart MS, Riffle DW, Boone WR. Computer-aided pattern analysis of temperature differentials. *J Manip Physiol Ther* 1989; 12(5):345-352.
34. Brand NE, Gizoni CM. Moire contouragraphy and infrared thermography: changes resulting from chiropractic adjustments. *J Manip Physiol Ther* 1982; 5(3): 113-119.
35. DeBoer K, et al. Inter- and intra-examiner reliability study of paraspinal infrared temperature measurements in normal students. *Research Forum* 1985; 2(1):4-12.
36. Plaughter G. Skin temperature assessment for neuromusculoskeletal abnormalities of the spinal column. *J Manip Physiol Ther* 1992;15(6):368.
37. Salminen, B.J., Misra, T. Inter- and Intra-examiner Reliability of the TyTron C-3000. Abstracts of the Eighth Annual Vertebral Subluxation Research Conference Sponsored by Sherman College of Straight Chiropractic. *Journal of Vertebral Subluxation Research* 2000; 4(1).
38. Senzon, S.A. The Theory of Chiropractic Pattern Analysis Based on the New Biology. Abstracts of the Eighth Annual Vertebral Subluxation Research Conference Sponsored by Sherman College of Straight Chiropractic. *Journal of Vertebral Subluxation Research* 2000; 4(1).
39. Hart, J.F. Analyzing the neurological interference component of the vertebral subluxation with the use of pattern analysis: A Case Report. Abstracts of Association of Chiropractic Colleges Eighth Annual Conference. *The Journal of Chiropractic Education* 2001; 15(1).
40. Amalu W, Tiscareno L, et al. Precision Radiology: Module 1 and 5- Applied Upper Cervical Biomechanics Course. Redwood City, Calif: International Upper Cervical Chiropractic Association, 1993. p.65-84.
41. Amalu W, Tiscareno L, et al. Precision Multivector Adjusting: Modules 3 and 7- Applied Upper Cervical Biomechanics Course. Redwood City, Calif: International Upper Cervical Chiropractic Association, 1993. p. 64-73.
42. Weiss HD, Stern BJ, Goldberg J. Post-traumatic migraine: chronic migraine precipitated by minor head or neck trauma. *Headache* 1991 Jul; 31 (7): 451-456.
43. Solomon S. Posttraumatic migraine. *Headache* 1998 Nov-Dec; 38(10): 772-8.
44. Margulies S. The postconcussion syndrome after mild head trauma part II: migraine underdiagnosed? *J Clin Neurosci* 2000 Nov; 7(6): 495-9.
45. Lane JC. Migraine in the athlete. *Semin Neurol* 2000; 20(2): 195-200.
46. Bettucci D, Aguggia M, Bolamperti L. Chronic post-traumatic headache associated with minor cranial trauma: a description of cephalalgic patterns. *Ital J Neurol Sci* 1998 Feb; 19(1):20-4.
47. Lemka M. Headache as the consequence of brain concussion and contusion with closed head injuries in children. *Neurol Neurochir Pol* 1999; 33 Suppl 5:37-48.
48. De Souza JA, Moriera Filho PF, Jevoux CD. Chronic post-traumatic headache after mild head injuries. *Arq Neuropsiquiatr* 1999 Jun; 57(2A): 243-8.
49. Packard RC. Epidemiology and pathogenesis of posttraumatic headache. *J Head Trauma Rehabil* Feb; 14(1): 9-21.
50. Obelieniene D, Bovim G, Schraeder H. Headache after whiplash: a historical cohort study outside the medico-legal context. *Cephalgia* 1998 Oct; 18(8): 559-64.
51. Keidel M, Diener HC. Post-traumatic headache. *Nervenarzt* 1997 Oct; 68(10): 769-77.
52. Gilkey SJ, Ramadan NM, Aurora TK. Cerebral blood flow in chronic posttraumatic headache. *Headache* 1997 Oct; 37(9): 583-7.
53. Packard RC, Ham LP. Pathogenesis of posttraumatic headache and migraine: a common headache pathway? *Headache* 1997 Mar; 37(3): 142-52.
54. Haas DC. Chronic post-traumatic headaches classified and compared with natural headaches. *Cephalalgia* 1996 Nov; 16(7): 486-93.
55. Plager DA, Purvin V. Migraine precipitated by head trauma in athletes. *Am J Ophthalmol* 1996 Aug; 122(2): 277-8.
56. Foletti G, Regli F. Characteristics of chronic headaches after whiplash injury. *Presse Med* 1995 Jul 1-8; 24(24): 1121-3.
57. Friedrichs ES. Migraine and childhood head trauma. *Headache* 1995 Mar; 35(3): 169.
58. Spierings EL, Foo DK, Young RR. Headaches in patients with traumatic lesions of the cervical spinal cord. *Headache* 1992 Jan; 32(1): 45-9.
59. Kennedy MP. Trauma-precipitated migrainous hemiparesis. *Ann Emerg Med* 1991 Sep; 20(9): 1023-4.
60. Sallis RE, Jones K. Prevalence of headaches in football players. *Med Sci Sports Exerc* 2000 Nov; 32(11): 1820-4.
61. McBeath JG, Nanda A. Roller coaster migraine: an underreported injury? *Headache* 2000 Oct; 40(9): 745-7.
62. Ferrari R. Whiplash-associated headache. *Cephalalgia* 1998 Oct; 18(8): 585-6.
63. Headache- //Hope Through Research. [www.ninds.nih.gov/health\\_and\\_medical/pubs/headche](http://www.ninds.nih.gov/health_and_medical/pubs/headche). Bethesda, Maryland: National Institute of Neurological Disorders and Stroke, National Institute of Health, July 2001.
64. Ebersberger A. Pathophysiology of migraine: models to explain the generation of migraine headache. *Anaesthetist* 2002 Aug; 51 (8): 661-7.
65. Hamel E. Current concepts of migraine pathophysiology. *Can J Clin Pharmacol* 1999 Autumn; 6 Suppl A; 9A-14A.
66. Gardner E. Pathways to the cerebral cortex for nerve impulses from joints. *Acta Anat* 1969; 56: 203-16.
67. Wyke B. The neurology of joints: a review of general principles. *Clin Rheum Dis* 1981; 7: 223-39.
68. Coote J. Somatosensory sources of afferent input as factors in aberrant autonomic, sensory, and motor function. In: Korr I. *The neurobiological mechanisms in manipulative therapy*. New York: Plenum, 1978: 91-127.
69. Denslow J, Korr I. Quantitative studies of chronic facilitation in human motoneuron pools. *Am J Physiol* 1987; 150: 229-38.
70. Korr I. Proprioceptors and the behavior of lesioned segments. In: Stark E. *Osteopathic medicine*. Acton, Mass: Publication Sciences Group, 1975: 183-99.